External morphology of the liver and the ramifications of the intrahepatic portal vein in the opossum (*Didelphis albiventris*)

Raul Antonio Fragoso Neto*

NETO, Raul Antonio Fragoso. External morphology of the liver and the ramifications of the intrahepatic portal vein in the opossum (*Didelphis albiventis*). *Salusvita*, Bauru, v. 19, n. 2, p. 63-71, 2000.

ABSTRACT

In the present report it is described the hepatic segmentation in the South American opossum (Didelphis albiventris) to understand the external morphology of the liver and the gross anatomic variations in the arrangement of the intrahepatic portal vein in this marsupial. Twenty-seven livers of opossums, of both sexes, young and adult, were studied through anatomical methods, i.e., corrosion casting, gross dissection and radiographs of intrahepatic branches of the portal vein. One liver, intact and conserved in formaldehyde, was examined for further description of the segmentation and correlation with the portal ramification. Externally, four main lobes form the liver of the opossum: right lateral, right medial, left medial and left lateral lobe. The caudate lobe is considered an extension of the inferior face of the right lateral hepatic lobe. There is great anatomical variability in the intrahepatic ramification of the portal vein to each one of these lobes.

Key words: portal vein, liver, anatomy, Marsupialia, Didelphidae

School of Sciences and Technology - UNESP - Campus of Presidente Prudente - Department of Physical therapy – - Rua Roberto Simonsen, nº305, Cx.P.467 CEP: 19060-900 / Presidente Prudente

INTRODUCTION

Marsupials are quite interesting biomedical models of primitive mammals. There are many studies related to capture, feeding, caging, anesthesia (Krupp and Quillin, 1964), body fluids sample collection (Jurgelski, 1974; Moore, 1984) and perfusion for tissue fixation for histology (Spagnoli et al., 1979).

In terms of comparatvie anatomy, in its philogenetic, functional, anatomic and evolutive aspects, the cardiac and vascular system has been

thoroughly studied (Forbes, 1881; Beddard, 1895, 1909; Parsons, 1896, 1903; Sweet, 1904; Mc Clure, 1900, 1903, 1906; Sonntag, 192la, 1921b; Pearson, 1940; Blair et al., 1942; Amoroso et al., 1943; Wood Jones, 1949; Wade, 1968; Dowd, 1969, 1974; Dom et al., 1970; Stonehouse e Gilmore, 1977; Figueiredo et al., 1979; Souza et al., 1982; Büll et al., 1992; Fragoso Neto, 1994; Fragoso Neto et al., 1997).

Hepatic segmentation in the liver of marsupials has not been fully studied and sometimes it is a controversial subject (Martin e Jones, 1834; Forbes, 1881; Beddard, 1895; Parsons, 1896, 1903; Sweet, 1904; Mackenzie, 1918 a, 1918 b; Wood Jones, 1949; Perrot, 1966; Stonehouse e Gilmore, 1977).

Rex, apud Elias and Petty (1952), reports that liver of mammals may be classified according to the lobulation, origin and distribution of portal vein branches. This seems to occur also in marsupials in which the vein divides itself in 2 main trunks at the moment it enters the liver.

Therefore, this study aims to describe the hepatic segmentation in the South American Opossum (*Didelphis albiventris*) in order to understand the external morphology of the liver and the anatomical variations of the intrahepatic portal vein branches, leading to a better knowledge of the division of hepatic lobules in this mammal.

MATERIAL AND METHDOS

Twenty-eight young and adult opossums (*Didelphis albiventris*) of both sexes, young and adult, were captured in the municipalities of Botucatu-SP and Presidente Prudente-SP. Animals were anesthetized and euthanasia was obtained by prolonged inhalation of chloroform. Afterwards, 27 animals underwent laparotomy to expose the abdominal contents and canulization of the extrahepatic portal vein with a needle directed towards the liver. Several liquids were injected to obtain colored contrast according to the following methods:

1. Vascular corrosion technique – in 22 animals the intrahepatic portal ramifications were injected with vinilacetate diluted in acetone and stained with color tone. After solidification of the material the liver was removed and immersed in pure chloridric acid for corrosion and study of the vascular molds, which were sketched.

2. Dissection – in three animals, the portal ramifications were filled with a gel material colored with heated Suvinil enamel. After filling, the canulated portion of the vein was closed with a knot and the liver removed and immersed for one week in a 10% formaline solution for fixation and hardening of the injected gel. The preparations were removed from the fixative solution, undergo careful dissection under magnification and the intraportal portal ramifications were sketched.

NETO, Raul Antonio Fragoso. External morphology of the liver and the ramifications of the intrahepatic portal vein in the opossum (*Didelphis albiventis*). *Salusvita*, Bauru, v. 19, n. 2, p. 63-71, 2000.

3. X Ray technique – in two animals, after injecting the portal ramifications with barium sulfate (Neobar), the livers were isolated, fixed in 10% formalin and X-rayed. Afterwards, the livers returned to the fixative liquid for proper conservation and the X rays of the portal ramifications were carefully sketched.

4. Analysis of preparations and report of results – in the remaining opossum (not injected) the liver was isolated and preserved in 10% formalin for sketches and study of the external morphology. The lobules were observed as well as fissures, and related structures in the visceral (FIGURE 1) and diaphragmatic aspects (FIGURE 2). The morphological terminology was according to Wood Jones (1949) for multilobulated liver, the general type of marsupials and was also based in the *NOMINA ANATOMICA VETERINARIA* (Simoens et al., 1994).

For the descriptive analysis of the segmentation in the liver the following points were considered:

a) predominance of the direction of portal branching inside each hepatic lobule

b) nomination of main vessels emerging from the common trunk of the portal vein: first order branches; second order branches (minor) originated from the primary division; and third order branches emerging from the anterior vessels (major)

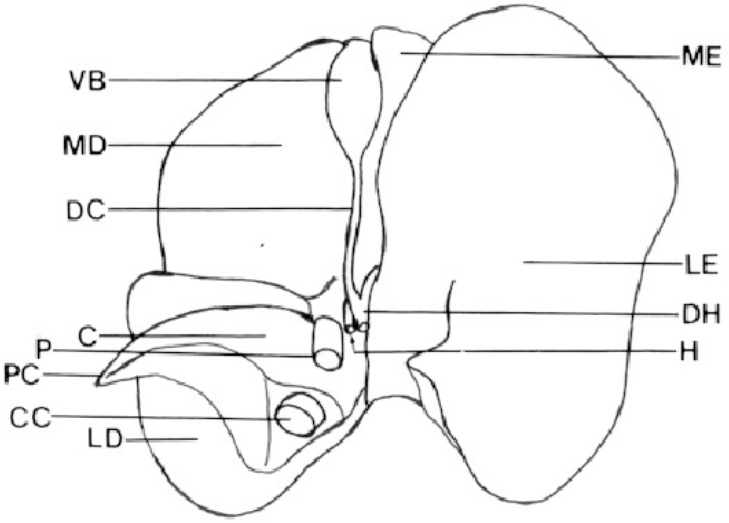

FIGURE 1. Diagram of the visceral aspect of the liver in the Didelphis albiventris (see text for details).

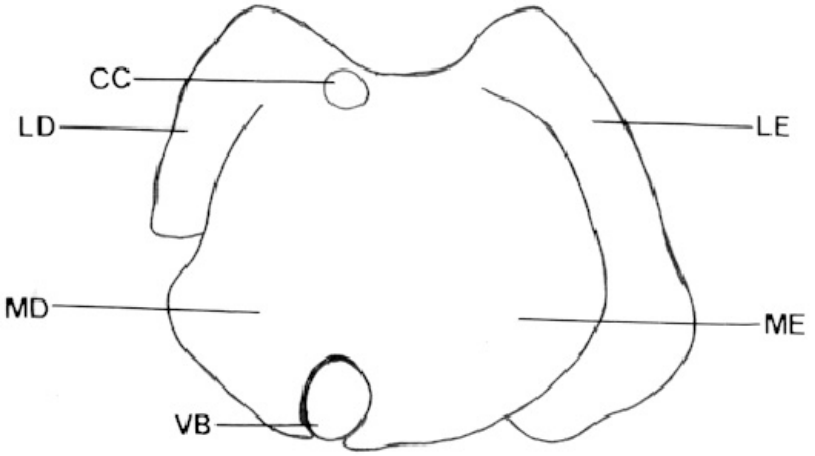

FIGURE 2. Diagram of the diaphragmatic aspect of the liver in the *Didelphis albiventris* (see text for details).

RESULTS AND DISCUSSION

External morphology of the liver (Didelphis albiventris)

The macroscopic observation of the opossum liver, from its visceral aspect, allowed the identification of 4 different lobules despite the caudate lobule with its long and prismatic caudate process (FIGURE 1). It was observed the gallbladder (VB) with the cystic duct (DC), the right lateral lobule (LD), the caudate lobule (C) with the caudate process (PC), the right medial lobule (MD), the left medial lobule (ME), the left lateral lobule (LE), the hepatic artery (H), the portal vein (P), the caudal Cava vein (CC) and the common hepatic duct (DH).

The portal triad, comprising portal vein, hepatic artery and common hepatic duct, are located in the hilar region of the organ.Therefore, the lateral right lobule, as shows this study, is similar to that of another marsupial *Dasycercus cristicauda* (Wood Jones, 1949) taking into consideration that the caudate process represents the caudal, prismatic and tiny continuity of this lobule.

The medial right lobule (or right central lobule according to Wood Jones, 1949) does not basically differ from the typical liver of marsupials. This lobule is separated from the left medial lobule by the interposition of the vesicular fosse and the sulcus where the cystic duct lays.

The medial left lobule (or left central lobule according to Wood Jones, 1949) has a strong similarity with its homologue in the *Dasycercus cristicauda*. In this regard, due to its large volume, it almost hides the left lateral lobule in its visceral aspect. In the diaphragmatic aspect (FIGURE 2) the right medial lobule and the left medial lobule are not clearly separated, thus, forming a seemingly sole and vast lobule. Most probably, this lobule is homologous to the median lobule reported by Martin Jones (1834) in the *Didelphis azarae*.

The great left lateral lobule, according to Wood Jones (1949) is also tongue shaped, occupying almost all the visceral aspect of the left side of the liver (FIGURE 1).

The gallbladder fosse in the *Didelphis albiventris* is an oval escavation which contains the gallbladder (FIGURE 2) which do not differ from observations by Wood Jones (1949) and Martin and Jones (1834). There is no evidence of a square lobule in the specimens observed in this study.

Main branching of the intrahepatic portal vein

The pattern of distribution of intrahepatic portal branches in the opossum *(Didelphis albiventris)* was studied in 10 organs (FIGURE 3): the portal vein trunk (P) gives primarily the right lateral branch (RLD) and, right after, the right medial branch (RMD) and continues directly as the left branch (RE), that is, as a straight prolongation of the portal trunk (P). A few small branches (rr) from the right lateral lobule go to the caudate lobule (C) and to its caudate process (PC). Usually, the left branch drains the lateral lobule (LE) and the left medial lobule (ME) in the manner of many small branches with a complex distribution.

However, in eight livers, the portal vein trunk (P) showed a variable pattern – a) bifurcation in two branches, right (RD) and left (RE) in two out of eight livers (FIGURE 4); b) trifurcating in a left branch and two more branches being one to the right lateral lobule and other to the right medial in three livers. c) Quadrifurcanting in two branches to the right lateral lobule, one branch to the right medial lobule and one branch to the left, which were found in two livers; d) the portal vein trunk may go as a sole trunk towards the left lateral lobule (left branch). As it progresses, it gives two thin branches to the right lateral lobule, one to the right medial lobule and another to the left medial lobule, which was found in the remaining liver.

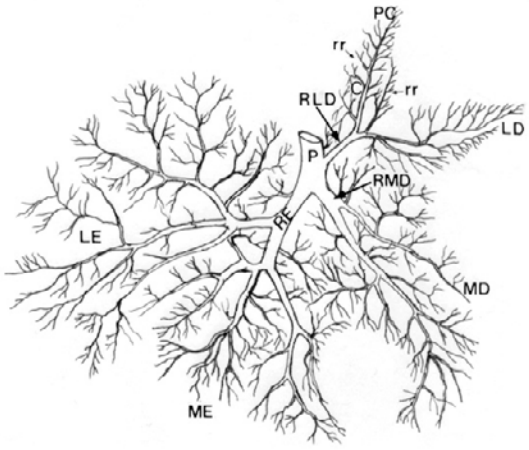

FIGURE 3. Diagram of the anatomical pattern of the distribution of intrahepatic portal branches in liver of the *Didelphis albiventris* (see text for details).

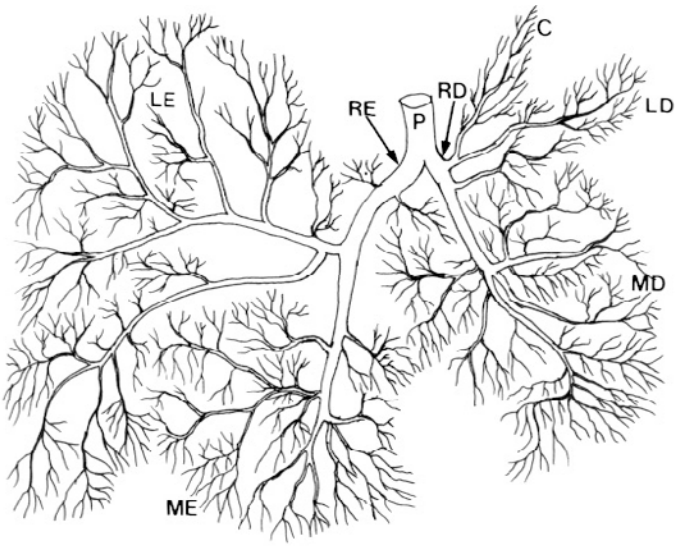

FIGURE 4. Diagram of the anatomical variation in the distribution of the portal intrahepatic braches in the liver of *Didelphis albiventris* (see text for details).

NETO, Raul Antonio Fragoso. External morphology of the liver and the ramifications of the intrahepatic portal vein in the opossum (*Didelphis albiventis*). *Salusvita*, Bauru, v. 19, n. 2, p. 63-71, 2000.

Behavior of hepatic lobules according to the vascularization of the portal vein.

In every preparation, with some variation, the right lateral lobule (LD), right medial (MD) and the caudate (C) get vascularized by the right branch (RD) or by small branching from the portal trunk. In the same way, the left lateral lobule (LE) and the left medial (ME) received many branches and little branches from the left branch (RE) of the portal vein trunk (FIGURE 4).

These observations on the complex venous distribution of the portal vein makes possible to distinguish the external liver lobules (FIGURE 1 and 2), taking into consideration, however, only the target of the first, second and third order branches of the portal trunk. The terminal branches are excluded which, in all preparations, were not observed due to the non-penetration of the contrast liquid which is an intrinsic limitation of the technique. Indeed, the corrosion technique was most adequate to the objective of this study due to the facility to observe the tridimentional disposition of the portal tree.

Sweet (1904), without commenting the behavior of the portal vein in the marsupial *Notoryctes sp*. does admit that this vein is divided in 3 vessels which are bound, separately, to the left and right portal branches. In the livers observed in this study, the right and left portal branches are probably homologous to the same branches reported in man by Elias and Petty (1952) and, in general, in marsupials by Rez, *apud* Elias and Petty (1952).

CONCLUSION

In this study, the division of the liver in the opossum *Delphis albiventris* follows the anatomical criteria of segmentation by means of fissures in its surface, four main lobules being identified: right lateral, right medial, left medial and left lateral. The caudate lobule, including its caudate process, is just an extension of the inferior aspect of the right lateral lobule. On the other hand, the right medial and left medial lobules are deeply escavated to host the gallbladder and constitute a sole lobule in the diaphragmatic aspect of the liver. As usual to the majority of mammals, no square lobule was observed in any liver or in any of its faces.

The first order branches (right and left branches) of the portal trunk do not undergo deep variation in the branching pattern if compared to the second order branches (branches to the right lateral lobule, right medial, left lateral and left medial) and, furthermore, those of third order which are limited to specific and minor sub-segments inside a liver lobule. This same principle is found clear in the venous vascular pattern of the liver of most animals, but the anatomical variations are specimen-specific to the opossum *Didelphis albiventris.*

BIBLIOGRAPHIC REFERENCES

AMOROSO, E. C., BARCLAY, A. E., FRANKLIN, K. J., PRICHARD, M. M. L. Incidence of bilateral anterior venae cavae in a series of Eutherian foetuses. *Proc. Zool. Soc. Lond.*, v. 113, p. 48 - 53, 1943.

BEDDARD, F. E. On the visceral anatomy and brain of *Dendrolagus bennetti. Proc. Zool. Soc. Lond.*, v. 1895, p. 131 - 137, 1895.

BEDDARD, F. E. On the postcaval vein and its branches in certain mammals. *Proc. Zool. Soc. Lond.*, v. 1909, p. 496 - 526, 1909.

BLAIR, D. M., DAVIES, F., FRANCIS, E. T. B. The conducting system of the marsupial heart. *Trans. Roy. Soc. Edin.*, v.60, n. 18, p.629 - 639, 1942.

BÜLL, M. L., SEULLNER, G., FRAGOSO NETO, R. A. Vascularização arterial do braço do gambá *(Didelphis albiventris* lhering, 1914 - Mammalia, Marsupialia, Didelphidae). *Acta Biol. Leopold*., v. 14, n.2, p. 109 - 122,1992.

DOM R., FISHER, B. L., MARTIN, G. F. The venous system of the head and the neck of the opossum *(Didelphis virginiana). J. Morphol.*, v. 132, p. 487 - 496, 1970.

DOWD, D. A. Gross features of the heart of a marsupial, *Trichosurus vulpecula. Acta Anat.*, v. 74, p. 454 - 471, 1969.

DOWD, D. A. The coronary vessels in the heart of a marsupial, *Trichosurus vulpecula. Acta Anat.*, v. 140, p. 47 - 56, 1974.

ELIAS, H., PETTY, D. Gross anatomy of the blood vessels and ducts within the human liver. *Am. J. Anat.*, v. 90, p. 59 - 111, 1952.

FIGUEIREDO, S. F., ALBUQUERQUE, J. F. G., SOUZA, W. M. Contribuição ao estudo da ramificação das artérias mesentéricas cranial e caudal em gambás *(Didelphis aurita). Científica*, Jaboticabal, v. 7, número especial, p. 51 - 53, 1979.

FORBES, W. A. On some points in the anatomy of the koala *(Phascolarctos cinereus). Proc. Zool. Soc .Lond.*, v. 1881, p. 180 - 195,1881.

FRAGOSO NETO, R. A. *Estudo anatômico da veia porta e suas tributárias no gambá* (*Didelphis albiventris*). Botucatu, 1994. 104 p. Tese (Doutorado em Ciências Biológicas) - Instituto de Biociências, Universidade Estadual Paulista.

FRAGOSO NETO, R. A., SEULLNER, G., CAMPOS, V. J. M. Gross anatomy of the portal vein and its tributaries in the opossum *(Didelphis albiventris). Anat. Histol. Embryol.*, v. 26, p. 227 - 229, 1997.

JURGELSKI, W. Jr. The opossum *(Didelphis virginíana* Kerr) as a biomedical model. Part 1: Rescarch perspective, husbandry, and laboratory technics. *Lab. Anim Sci.*, v. 24, n. 2, p. 3 76 - 403, 1974.

KRUPP, J. H., QUILLIN, R. A review of the use of the opossum for research husbandry, experimental techniques and routine health measures. *Lab. Anim. Care*, v. 14, n. 3, p. 189 - 194, 1964.

MACKENZIE, W. C. *The liver, spleen, pancreas, peritoneal relations and biliary system in monotremes and marsupials.* Melbourne: Crithley Parker, Australia, 1918 a.

MACKENZIE, W. C. *The gastrointestinal tract in monotremes and marsupials.* Melbourne: Crithley Parker, Austrafia, 1918 b.

MARTIN, W., JONES, R. Notes on the dissection of Azara's opossum *(Didelphis azarae Temm.). Proc. Zool .Soc. Lond.*, v. 1834, p. 101 - 104,1834.

McCLURE, C. F. W. The variations of the venous system in *Didelphis virginiana. Anat Anz.* v. 18, p. 441 - 460, 1900.

McCLURE, C. F. W. A contribution to the anatomy and development of the venous system of *Didelphís marsupialis* (L). Part 1. Anatomy. *Am. J Anat.*, v. 2, n. 3, p. 371 - 404, 1903.

McCLURE, C. F. W. A contribution to the anatomy and development of the venous system of *Didelphis marsupialis* (L). Part 1. Anatomy. *Am. J. Anat.*, v. 5, n. 2, p. 163 - 226, 1906.

NETO, Raul Antonio Fragoso. External morphology of the liver and the ramifications of the intrahepatic portal vein in the opossum (*Didelphis albiventis*). *Salusvita*, Bauru, v. 19, n. 2, p. 63-71, 2000.

MOORE, D. M. A simple technique for blood colection in the opossum (*Didelphis virginiana*)**.** *Lab. Anim***,** v. 18, n. 1, p. 52 - 54, 1984.

PARSONS, F. G. On the anatomy of *Petrogale xanthopus*, compared with that the others Kangaroos. *Proc. Zool. Soc.. Lond***.,** v. 1896, p. 683 - 714, 1896.

PARSONS, F. G. On the anatomy of the pig - footed bandicoot *(Choeropus castanotis). J. Linnean Soc. Zool.*, v.29, p. 64 - 80, 1903.

PEARSON, J. Notes on the blood system of the Marsupialia. *Pap. & Proc. Roy. Tasmania***,** v. 1939, p. 77 - 94, 1940.

PERROT, J. W. The peritoneum of *Trichosurus vulpecula. Anat. Rec.*, v. 154, p.295 - 304, 1966.

SIMOENS, P., MÜNSTER, W., SAAR, L.I., DE VOS, N.R., VOLLMERRAUS, B. Angiologia. ln: *NOMINA ANATOMICA VETERINARIA*, Zurich: Swítzerland & Ithaca, New York, USA, World Association of Veterinary Anatomists. p. 63 - 106, 1994.

SONNTAG, C. F. The comparative anatomy of the koala *(Phascolarctos cinereus)* and vulpine phalanger *(Trichosurus vulpecula). Proc. Zool. Soc. Lond.*, v. 192 1, p. 547 - 577, 1921 a.

SONNTAG, C. F. Contributions to the visceral anatomy and myology of the Marsupialia. *Proc. Zool. Soc. Lond*, v. 1921, p. 851 - 882, 1921 b.

SOUZA, W. M., MIGLINO, M. A., ALBUQUERQUE, J. F. G. Contribuição ao estudo dos colaterais calibrosos do arco aórtico no gambá *(Didelphis aurita). Arq. Biol. Tecnol.(Curitiba)*, v. 25, n.2, p. 207 - 209, 1982.

SPAGNOLI, D. B., FIDLER, S. F., CARMICHAEL, S. W., CULBERSON, J. L. Perfusion fixation of the newborn opossum: Equipament and Techniques. *Lab. Anim. Sci.*, v. 29, n.2, p. 246 - 248, 1979.

STONEHOUSE, B., GIILMORE, D. *The biology of marsupials*. London: Mc Millan, 1977. 486p.

SWEET, G. Contributions to our knowledge of the anatomy of *Notoryctes typhlops*, Stirling. Parts I and II. *Proc. Roy. Soc. Victoria***,** v. 17, p. 76 - 111, 1904.

WADE, O. Structural characteristics of the heart of the wombat, *Lasiorhinus latifrons* Owen. *Amer. Midd. Nat***.,** v. 80, n. 1, p. 266 - 268, 1968.

WOOD JONES, F. A study of a generalized marsupial *(Dasycercus cristicauda* Kreft). *Trans. Zool. Soc. Lond***.,** v. 26, n. 1, p. 409 - 501, 1949.