

RADIOGRAPHIC EVALUATION OF ENDODONTIC TREATMENT AND RADICULAR RETAINER QUALITY

Eliza Burlamaqui Klautau¹

Patrícia Silva e Souza²

Camila Maria Trindade Martins Barros³

Viviane Garcia⁴

Kalena de Melo Maranhão⁵

¹DDS, PhD, Assistant Professor, UFPA'S Dental School – Belém/PA

²DDS, PhD, Assistant Professor, CESUPA'S Dental School – Belém/PA

³DDS, Undergraduate student, CESUPA'S Dental School – Belém/PA

⁴DDS, Undergraduate student, CESUPA'S Dental School – Belém/PA

⁵DDS, MSc, Undergraduate student, UFPA'S Dental School – Belém/PA

KLAUTAU, Eliza Burlamarqui et al. Radiographic evaluation of endodontic treatment and radicular retainer quality. *Salusvita*, Bauru, v. 28, n. 1, p. 21-29, 2009.

ABSTRACT

The purpose of this study was to evaluate the quality of the coronal restoration, radicular retainer, periapical status and root fillings scored on radiographic basis of endodontically treated teeth. A total of 192 periapical radiographs were randomly selected from CESUPA'S Dental School patients. According to the radiographic criteria, the technical quality was categorized as 'adequate' or 'inadequate'. The data analyzed by statistical X^2 test demonstrated that 53.64% had inadequate endodontic treatment; teeth with an adequate root filling were associated with a better periapical status than teeth with inadequate root filling (65.1% vs. 34.89%); teeth with adequate and inadequate coronal restorations were 48,14% and 51.85%, respectively. This difference was not statistically significant and the rate of inadequate root canal post and core was 58.33%.

Key words: Endodontic treatment. Radicular retainer. Rehabilitator element.

Recebido em: abril de 2007

Aceito em: julho de 2008

RESUMO

O propósito deste estudo foi avaliar radiograficamente a qualidade dos retentores intra-radiculares, região periapical e tratamentos endodônticos. Um total de 192 radiografias periapicais foram selecionadas da Clínica Odontológica do Centro Universitário do Pará – CESUPA. De acordo com os critérios radiográficos, a qualidade foi categorizada como adequada ou inadequada. Os dados analisados por meio do teste estatístico X^2 demonstraram que o tratamento endodôntico apresentou inadequado em 53.64%; a região periapical foi inadequada em 34.89%; os elementos reabilitadores presentes apresentaram adaptação cervical inadequada em 51.85% e os retentores intra-radiculares foram executados inadequadamente em 58.33%.

Palavras-chave: Tratamento endodôntico. Retentor intra-radicular. Elemento reabilitador. Região periapical.

INTRODUCTION

Posts and cores are used in the reconstruction of coronal structure of endodontically treated teeth. They provide retention and stability of the prosthodontic, providing to the remaining dental structure biomechanic conditions to keep the prosthetic function and substituting the absent dental structure.

So that a tooth can receive a radicular retainer, it needs a correct diagnosis of the remaining structures conditions, the radicular anatomy, periodontium and the root fillings.

In addition, recent studies have demonstrated that the coronal leakage is one of the determinative factors of the failure of the endodontic treatment. Thus, a good marginal sealing of the prosthetic crown is important for the success of endodontic therapy and rehabilitation (PRADO, 2002; HOMMEZ et al., 2002; SEGURAGEA et al., 2004; RENNÓ, 2005; SIQUEIRA JR et al., 2005; FERREIRA, 2006).

The purpose of this study was to evaluate the quality of the coronal restoration, radicular retainer, periapical status and root fillings scored on periapical radiographic of endodontically treated teeth.

KLAUTAU, Eliza Burlamarqui et al. Radiographic evaluation of endodontic treatment and radicular retainer quality. *Salusvita*, Bauru, v. 28, n. 1, p. 21-29, 2009.

MATERIALS AND METHOD

The material consisted of 192 periapical radiographs randomly selected from CESUPA'S Dental School patients. The Ethics Committee approved the study design. All periapical radiographs were evaluated using an x-ray viewer with 10x magnification and millimeter ruler. The coronal restoration, radicular retainer, root canal treatment and the periapical condition were scored according to the listed criteria:

Root canal treatment

- 1 - Root filling terminating 3 mm from the radiographic apex (adequate).
- 2 - Homogeneous root filling, good condensation, no voids visible (adequate).

Periapical condition

- 1 - continuous lamina dura (adequate)
- 2 - Width of the periodontal ligament normal (adequate)
- 3 - Absence of periapical radiolucency (adequate)

Post and core systems

- 1 - Root filling terminating 3 mm from the radiographic apex or half length of the root or one third the diameter of the root (adequate)
- 2 - Radicular retainer fills the removed space of the root canal (adequate)

Coronal restoration

- 1 - Intact restoration without signs of leakage (adequate).
- 2 - The data obtained were analyzed by statistical X² test.

RESULTS

Figure 1 shows the quality of root canal treatment. From 192 radiographics, 103 (53.64%) presented inadequate treatment and only 89 (46.35%) presented adequate results.

In the periapical region, 67 teeth (34.89%) presented inadequate, while 125 (65.1%) was considered adequate. These percentages were compared with the success and failure cited previously considering the consequence observed in the periapical region in function of the quality of the endodontic treatment (Table 1).

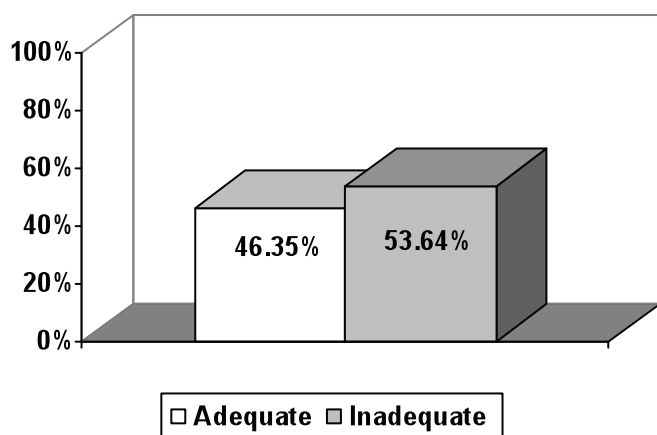


Figure 1 - Quality of endodontic treatment, percentage of adequate/inadequate

Table 1 - Test qui-square for the found and waited results of the periapical region.

Periapical Region	Found	%	Waited	%
Adequate	125	65,1	165	86
Inadequate	67	34,89	27	14

Data source: Research protocol ($p < 0,01$)

In accordance with the demonstrated in Table 1 and illustrating in Figure 2, the difference statistics between the found results and the waited are highly significant ($p < 0,01$).

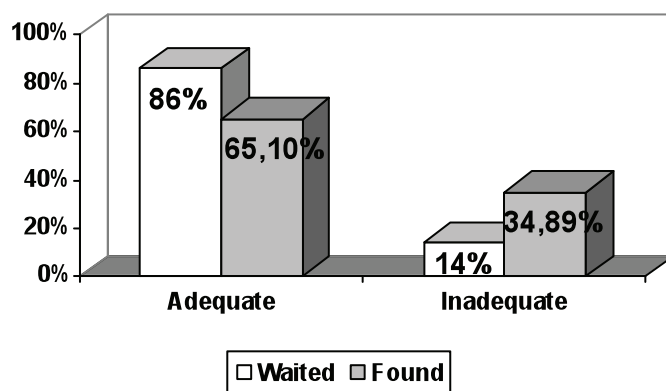


Figure 2 - Analysis of the periapical region observed in comparison with the waited

Related to the radicular preparation of 192 analyzed teeth, it was observed that: 109 (56.77%) presented inadequate and 83 (43.22%)

KLAUTAU, Eliza
 Burlamarqui et
 al. Radiographic
 evaluation
 of endodontic
 treatment and
 radicular retainer
 quality. *Salusvita*,
 Bauru, v. 28, n. 1,
 p. 21-29, 2009.

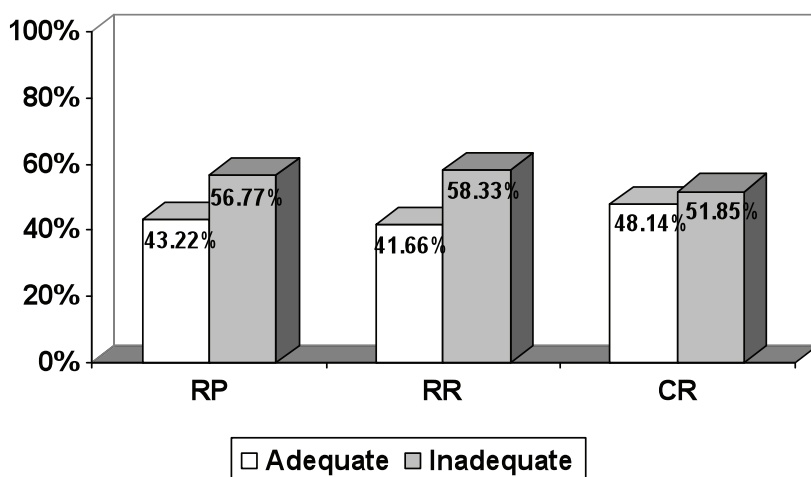


Figure 3 - Analysis of the prosthetic rehabilitation

adequate. In relation to the radicular retainer, 112 (58.33%) were inadequate and 80 (41.66%) adequate. For the rehabilitator element was observed only its presence in 108 teeth being that 56 (51.85%) the adaptation was inadequate and 52 (48.14%) adequate (Table 2).

Table 2 - Test qui-square for analysis of the prosthetic rehabilitation.

Prosthetic Rehabilitation	Adequate	%	Inadequate	%
RP	83	43.22	109	56.77
RR	80	41.66	112	58.33
CR	52	48.14	56	51.85

Data source: Research protocol ($p > 0,05$)

Finally, was observed on Table 2 and illustrated in Figure 3 that the difference was not statistical significant between the three factors analyzed for prosthetic rehabilitation.

DISCUSSION

The results in research shown that the percentage of endodontic treatment is inadequate (53.64%). These data are similar to the one found by Lage Marques et al. (1996).

Separately observing the item used for the evaluation of these treatments (filling material, filling material homogeneity and limit of the filling root canal), was observed that: the filling material was absent in 4.16% of the sample; the limit of the filling root canal was inadequate in 27.71% and the filling material homogeneity was inadequate in 40.21%, this last item was the main failure factor of the endodontic treatments in this research.

Kirkevang et al. (2000) evidenced that 57.8% of teeth with endodontic treatment without adequate homogeneity had alteration in the periapical region, while 67.6% of teeth with inadequate endodontic treatment limit had modified periapical region, concluding that the filling root canal limit is the main factor in the failure of the endodontic treatment when compared with the homogeneity. These results are not in accordance with what was observed in research, where the major failure percentage was attributed to the lack homogeneity of the filling material.

In turn, Lopes et al. (1997) observed that 50.4% of analyzed teeth had incorrect endodontics treatments, being 39% inadequate filling root canal, taking such the filling root canal limit as the filling material homogeneity and 11.4% absence of the filling material. In research was observed similar results, evidenced that the lack of the filling material was not the responsible for the treatment failure.

In relation to the periapical region, was observed that 34.89% were inadequate, same results were found by Kirkevang et al. (2000), which also found a great percentage, reaching 52.3% of compromised periapical region.

19.27% of these cases showed signs of periapical injury; 32.29% had periodontal ligament thickening and in 32.29% the lamina dura was not continuous. Thus, the last 2 parameters had influence on periapical health.

The present study limited itself to a radiographic analysis, not considering the clinic rules.

56.77% of the periapical radiographic had inadequate radicular preparation. The remaining filling material had little influence over the radicular preparation failure (14.58%). So, the remaining adequate filling material, provides an effective apical sealing, influencing the periapical status (HOMMEZ et al., 2002; SEGURA-EGEA et al., 2004; SIQUEIRA JR et al., 2005).

58.33% of the radicular retainers were inadequated. 44.70% of the retainer length were inadequated, while 29.68% of the diameter were inadequated.

Some authors praise that the ideal length for the radicular retainer should be two third the length of the root (BARRETO, 1989; CARMO, 1997; BONFANTE et al., 2000; LUCAS et al., 2001; PRADO, 2002; FERREIRA 2006), other admit that the length should be at least half length of the root the same length of the crown or half of the root osseous implantation in its alveolus (FALLEIROS JR; COLLESI, 1988).

Analyzing the diameter of the radicular retainer, the majority of the authors agrees that it must have one third the diameter of the root,

KLAUTAU, Eliza Burlamarqui et al. Radiograpchi evaluation os edodontic treatment and radicular retainer quality. *Salusvita*, Bauru, v. 28, n. 1, p. 21-29, 2009.

KLAUTAU, Eliza
Burlamarqui et
al. Radiographic
evaluation
of endodontic
treatment and
radicular retainer
quality. *Salusvita*,
Bauru, v. 28, n. 1,
p. 21-29, 2009.

preserving 1 to 1,5mm of dentine around its whole extension (FALLEIROS JR; COLLESI, 1988; SEADI; NOCCHI, 1995; CARMO, 1997; LUCAS et al., 2001; PRADO, 2002).

In this analysis was verified that the failure was more influenced by the inadequate length of the radicular retainer than the diameter, as well as told Nagle et al. (2001).

The percentage of inadequate length of the radicular retainer was bigger when compared with the removal of filling root canal in length, although these had to present equal values. It's apply to some dental elements that had it radicular preparation done correctly, however it retainer had insufficient length. These cases were observed, most of the time on cast core and this imperfection is related, to the incorrect root canal molding with duralay (RENNÓ, 2005).

In relation to the coronal restoration was observed that it was present in only 108 periapical radiographic (56.25%), and its cervical adaptation showed inadequate in 51.85%, this percentage is similar to the one found by Lage Marques et al. (1996).

The absence of the coronal restoration can compromise the success of the endodontic treatment, once it facilitates the contamination of the root canal by microorganisms infiltration in this region.

CONCLUSION

- The endodontic treatment presented inadequate in 53.64% of the evaluated cases;
- The periapical region presented inadequate characteristics in 34.89%, being the item that presented the lesser failure percentage;
- The radicular retainer were inadequate in 58.33% and its radicular preparation in 56.77%;
- The coronal restoration presented inadequate cervical adaptation in 51.85%.

REFERENCES

- BARRETO, R. C. Núcleo em prótese fixa. *RGO*, v. 37, n. 3, p. 231-35, 1989.
- BONFANTE, G. et al. Avaliação radiográfica de núcleos metálicos fundidos intra-radulares. *RGO*, v. 48, n. 3, p. 170-74, 2000.

CARMO, M. R. C. Considerações sobre o sistema pino núcleo na restauração de dentes extensamente destruídos. *JBC*, v. 1, n. 4, p. 28-31, 1997.

FALLEIROS JR, H. B.; COLLESI, R. R. Considerações a respeito do preparo intra-radicular na reconstituição de dentes tratados endodonticamente. *Rev Ass Paul Cirur Dent*, v. 42, n. 2, p. 155-57, 1988.

FERREIRA, T.J.C. Resistência à fratura de dentes bovinos tratados endodonticamente e preparados para facetas diretas: efeitos de pinos e agentes cimentantes. São Paulo, 2006. Dissertação (Mestrado em Dentística), Faculdade de Odontologia da Universidade de Taubaté, 2006.

HOMMEZ, G. M. et al. Periapical health related to the quality of coronal restorations and root fillings. *Int Endod J*, v. 35, n. 8, p. 680-689, 2002.

KIRKEVANG, L. L. et al. Periapical status and quality of root fillings and coronal restorations in a Danish population. *Int Endod J*, v. 33, p. 509-15, 2000.

LAGE MARQUES, J. L. et al. Análise radiográfica da qualidade do tratamento endodôntico e suas interações. *Rev Bras Odontol*, v. 3, n. 3, p. 11-15, 1996.

LOPES, H. P. et al. Retentores intra-radulares: análise radiográfica do comprimento do pino e da condição da obturação do canal radicular. *Rev Bras Odontol*, v. 54, n. 5, p. 277-80, 1997.

LUCAS, L. V. M. et al. Tratamento protético de dentes despolpados: preparo intra-radicular e opções de restaurações: Revisão bibliográfica. *Rev Ass Paul Cirur Dent*, v. 22, n. 2, p. 20-24, 2001.

NAGLE, M. M. et al. Avaliação radiográfica de dentes submetidos a núcleos metálicos fundidos na clínica integrada da faculdade de odontologia de Araraquara - UNESP. *PCL*, v. 3, n. 16, p. 487-91, 2001.

PRADO, L. S. Resistência à fratura de raízes restauradas com pinos intra-radulares. São Paulo, 2002. Monografia (Especialização em Prótese Dentária), Faculdade de Odontologia de Bauru, 2002.

RENNÓ, D.G. Estudo in vitro da adaptação de redutores intra-radulares fundidos, modelados com diferentes resinas acrílicas autopolimerizáveis. São Paulo, 2005. Dissertação (Mestrado em Prótese Dentária), Faculdade de Odontologia da USP, 2005.

SEADI, R. S; NOCCHI, P. Prótese parcial fixa: confecção e cimentação de núcleos fundidos visando a conservação de remanescentes

KLAUTAU, Eliza Burlamarqui et al. Radiographic evaluation of endodontic treatment and radicular retainer quality. *Salusvita*, Bauru, v. 28, n. 1, p. 21-29, 2009.

KLAUTAU, Eliza
Burlamarqui et
al. Radiographic
evaluation
of endodontic
treatment and
radicular retainer
quality. *Salusvita*,
Bauru, v. 28, n. 1,
p. 21-29, 2009.

dentários extensamente debilitados. *Rev Odonto Ciênc*, v. 10, n. 20,
p. 191-202, 1995.

SEGURA-EGEA, J. I. et al. Periapical status and quality of root
fillings and coronal restorations in an adult Spanish population. *Int
Endod J*, v. 37, n. 8, p. 525-30, 2004.

SIQUEIRA JR, J. F. et al. Periradicular status related to the quality
of coronal restorations and root canal fillings in a Brazilian popula-
tion. *Oral Surg Oral Med Oral Pathol Oral Radiol Endod*, v. 100, p.
369-374, 2005.